



PATIENT

Rusty Oosterom

SPECIES

Feline

BREED

DSH

SEX

Male Neutered

AGE

~13.5 years

WEIGHT

17.4lbs

INTERPRETED BY

Maggie Machen Lamy,
DVM, DACVIM
(Cardiology)

IMAGING PERFORMED BY

Brian Barnes, DVM

HOSPITAL NAME

Westview Veterinary
Hospital

REFERRING VET

Dr. Barnes

INVOICE

22249

DATE

12/2/21

PRESENTING CLINICAL SIGNS

History: Recheck echo. History of Hyperthyroidism (uncontrolled on previous exam); T4 now controlled with Tapazole 5mg BID. Doing well. BP: 198mmHg. Sedation used: Ace/Torb
-Abnormal PE/Chem/CBC/UA Results: History of increased BNP 177.

-Pertinent previous echo findings (5/2021 MML): Mild to moderate LVH, no LAE. IVSd: 0.65, LVWd: 0.72, LA: 1.0.

ECHOCARDIOGRAM FINDINGS

2D, m-mode, color flow and doppler imaging is available. The left ventricular wall is mildly increased in dimension with regions of irregularity. There is a diffusely hyperechoic endocardium consistent with fibrosis. Mild symmetric papillary muscle hypertrophy and remodeling. The right ventricle is subjectively normal in size and morphology. There is mild left atrial enlargement present. No right atrial enlargement present. Normal RVOT velocity. Trace TR. Normal LVOT velocity. There is no obvious systolic anterior motion (SAM) of the mitral valve present. Trace MR. There is no pericardial effusion noted. No pleural effusion appreciated. No obvious cardiac tumors.

CARDIAC CHART

FELINE CARDIAC PARAMETERS	BODY WEIGHT (kg)	HR (BPM)	IVSd (cm) <small>(Moise, Pipers)</small>	LVIDd (cm) <small>(Moise, Pipers)</small>	LVWd (cm) <small>(Moise, Pipers)</small>	FS (%)	EF (%)
NORMAL PARAMETER	-----	150-240	0.35-0.55	<2 (mean 1.5)	3.5-0.55	35-67	80-100
PATIENT	7.91	NM	0.68	1.2	0.69	69	96
FELINE CARDIAC PARAMETERS	LA/AO <small>(Boon)</small>	LA/AO HEART BASE (Swe) <small>(Abbott)</small>	LA 2D short axis Base view (cm) <small>(Abbott)</small>		LVOT VEL (m/s)	RVOT VEL (m/s)	E max (m/s)
NORMAL	<1.5	<1.3	<1.2		<1.6	<1.3	<0.9
PATIENT	1.4	1.2	1.2		1.1	1.0	NM
<p><i>*Note: All measurements based upon multi-modal images and methods. An average value is reported.</i> Adapted from June Boon, Veterinary Echocardiography, 1998 Abbott J & MacLean H JVIM 2006;20: 111-119, Moise et al. Am J Vet Res 47:1476, 1986. Pipers et al. Am J Vet Res 40:882, 1979.</p>							

INTERPRETATION OF THE FINDINGS & FURTHER RECOMMENDATIONS

Largely unchanged structural abnormalities. Mild LVH persists despite thyroid control which likely reflects at least some component of primary disease in this patient. The LA remains normal indicating low risk for complication at this time. No additional issues are identified.

No medications remain indicated. Continue monitoring of thyroid, blood pressure and structural disease is recommended going forward. Prognosis remains guarded long term, given the highly variable rates of progression with subclinical cardiomyopathy.

Monitor at home for any respiratory issues or signs of blood clot events (neurologic change, paralysis, etc.).



PATIENT

Rusty Oosterom

SPECIES

Feline

BREED

DSH

SEX

Male Neutered

AGE

~13.5 years

WEIGHT

17.4lbs

INTERPRETED BY

Maggie Machen Lamy,
DVM, DACVIM
(Cardiology)

**IMAGING
PERFORMED BY**

Brian Barnes, DVM

HOSPITAL NAME

Westview Veterinary
Hospital

REFERRING VET

Dr. Barnes

INVOICE

22249

DATE

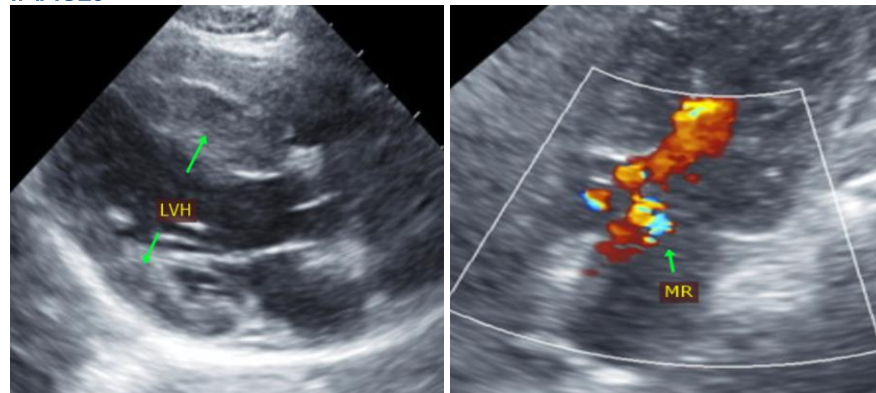
12/2/21

Anesthetic risk is considered mild, however judicious fluid administration is advised if needed with careful RR/RE monitoring to screen for fluid overload. Additionally, drugs that stimulate heart rate should be avoided unless clinically necessary (glycopyrrolate, atropine). Risk for complication with steroid use typically follows LA dilation, which in this case is mildly elevated. If needed, monitoring of RR/RE is advised particularly in the initiation phase.

Plan: A screening blood pressure and T4 are recommended every 6 months lifelong.

A recheck echocardiogram is recommended in 6-12 months to assess for progression, sooner if any issues arise in the interim.

IMAGES



The information and recommendations provided are based on the images presented by the referring veterinarian. No evaluation can be communicated regarding pathology that was not visible in the image/video clips provided.

Thank you for this referral. This report was generated using transcription software, and minor dictation errors may be present. If the clinical or image interpretation does not parallel your findings or if I can be of any further assistance, please contact me.

Maggie Machen Lamy, DVM
Diplomate of the American College of Veterinary Internal Medicine (Cardiology)
info@sonopath.com